

A Triple Negative Breast Cancer That Does Not Require Chemotherapy: A Case Report of Adenoid Cystic Carcinoma of the Breast

Mohammed Al Duhileb^{1*}, MD; Jamila Alazhri¹, MD; Miral Mashhour², MD; Ahmed Alwbari³, MD

¹King Fahad Specialist Hospital-Dammam, Department of Surgery

²King Fahad Specialist Hospital-Dammam, Department of Pathology

³King Fahad Specialist Hospital-Dammam, Department of Medical Oncology

***Corresponding author:** Dr Mohammed Al Duhileb, Breast and endocrine surgery, King Fahad Specialist-Dammam. Saudi Arabia. Tel: +966595909590; Email: duhailebm@hotmail.com

Citation: Al Duhileb M, Alazhri J, Mashhour M, Ahmed Alwbari (2020) A Triple Negative Breast Cancer That Does Not Require Chemotherapy: A Case Report of Adenoid Cystic Carcinoma of the Breast. Annal Cas Rep Rev: ACRR-145.

Received Date: 20 July 2020; **Accepted Date:** 27 July 2020; **Published Date:** 05 August 2020

Abstract

Background: Adenoid cystic carcinoma (ACC) of the breast is a rare neoplasm accounting for 0.1%. It is of special interest because of its favorable prognosis and unique management approach.

Case Presentation: A 42-year-old female presented with a palpable lump in the left breast. Tru-cut biopsy revealed invasive ductal carcinoma ACC form. A breast conserving surgery with sentinel lymph node biopsy were performed. Histopathology revealed ACC with estrogen receptor negative, progesterone receptor negative and HER2-Neu negative type. The multidisciplinary tumor board recommended that neither neoadjuvant nor adjuvant systemic treatment to be offered to this patient. She received adjuvant radiation therapy.

In this report, we present a comprehensive review of the literature and discuss the unique characteristics of ACC, its prognosis compared to other triple negative breast cancer subtypes, and the evidence as well as the controversy in different treatment approaches.

Keywords: Adenoid Cystic Carcinoma, Breast Cancer.

Introduction

Adenoid cystic carcinoma (ACC) of the breast is a rare variant of breast cancer that has no standard of care in place. Salivary gland tumors having the same histological pattern as ACC of the breast were first termed "cylindroma" by Billroth. ACC is more common in women in their fifth or sixth decade. Most patients present with a dominant retroareolar tender breast mass on palpation. Histologically, it shows both epithelial and myoepithelial components and resembles a well-known tumor of the salivary gland origin known by the same name [1].

Cytologically, the tumor shows a typical pattern: globules of mucus surrounded by epithelial cells with little cytoplasm and small hyperchromatic nuclei. ACC of the breast is generally estrogen receptor (ER), progesterone receptor (PR) and HER2-Neu negative. ACC reportedly has a better prognosis than most forms of breast cancer and the incidence of axillary lymph node metastases is lower. Distant metastases are uncommon, but when they occur they tend to do so without prior lymph node involvement [2]. We present the following case in accordance with the CARE reporting checklist.

Incidence: 0.1% of all breast cancers
Age: 30-90 (most common in 5th and 6th decade)
Most common presentation: painful mass in the retroareolar region of the breast
Ultrasonography: hypoechoic solid lesion or heterogeneous appearance
Mammography: benign-appearing, lobulated mass or irregular mass or asymmetric developing density
Axillary involvement: rare (0.8% to 2%)
Distant metastases: rare (most commonly in the lungs)
Hormone receptors: ER (-), PR (-), HER2-Neu (-)
Surgical treatment: Simple mastectomy Lumpectomy + postoperative radiotherapy Modified radical mastectomy
Radiotherapy: after breast-conserving surgery
Chemotherapy: controversial
Hormonotherapy: limited (triple negative in most cases)
Overall survival: 5 years: 88% to 98% 10 years: 86% to 95%

Case Report

Clinical presentation

The patient is a 42-year-old, premenopausal lady who presented to the breast surgical oncology clinic with a left breast mass for 5-months duration. The mass was in the periareolar area, painless, not increasing in size, no skin changes, nipple changes or nipple discharge.

The patient gave a history of hypertension, a negative history of oral contraceptive pills (OCP) use and a negative family history of breast or ovarian cancers.

Breast examination showed left periareolar, non-tender palpable mass at 3 o'clock position, close to the nipple,

superficially located but not attached to the skin, measuring about 1.5x1 cm. The nipple was normal in shape with no nipple discharge and no skin tethering. There were no other palpable masses in the same or the contralateral breast nor in both axillae.

Diagnostic workup

Mammogram revealed a 1-cm irregular mass at upper outer quadrant in the left breast and another suspicious mass at the retroareolar region, likely representing a multifocal pathology in the left breast. No evidence of suspicious findings in the contralateral breast nor in both axillae (Figure.1).

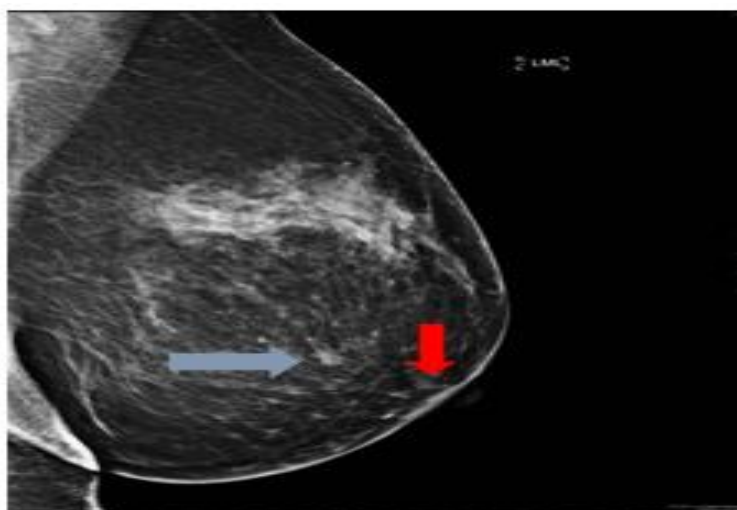


Figure 1: MLO view of the left breast showing the palpable retroareolar mass (red arrow) and another deeper irregular non-palpable mass (blue arrow) representing the multifocal disease in the left breast.

Bilateral breasts ultrasound showed two suspicious masses in left breast; one at retroareolar 3 o'clock area and the other was at 3-4 o'clock (Figure.2). There were no

suspicious findings in the contralateral breast nor in both axillae.

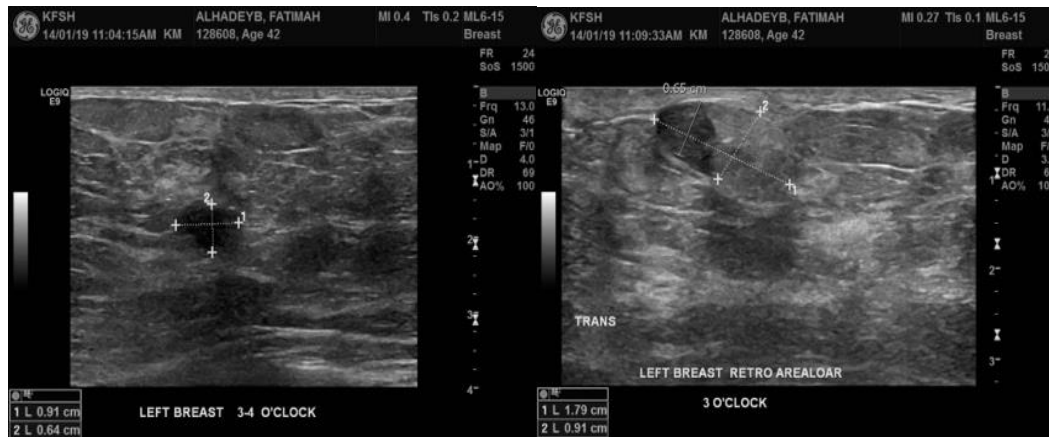


Figure 2: Ultrasound of the breast showing the two suspicious masses in left breast; one at retroareolar 3 o'clock area and the other one at 3-4 o'clock.

Ultrasound guided Tru-cut biopsy of both lesion at left breast 3 o'clock superficial mass and the 3-4 o'clock deeper mass was done. Histopathology of both revealed invasive breast cancer form of adenoid cystic carcinoma (Salivary gland type), ER negative, PR negative, HER2-Neu negative and Ki67 of 15%.

MRI Breast was consistent with the mammogram and ultrasound findings with a 1.2 cm mass in the left breast, consistent with biopsy proven cancer and another 1 cm mass at the retroareolar region in the left breast, suggestive of multifocal disease, BIRADS VI.

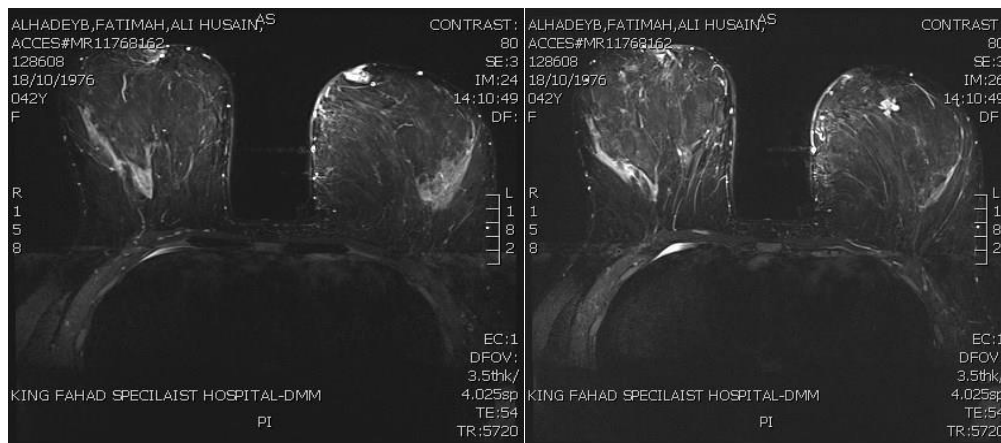


Figure 3: MRI breast showing a 1-cm mass at the retroareolar region and another 1.2 cm mass in the left breast, consistent with biopsy proven multifocal cancer

Metastatic workup

No evidence of metastasis was found on CT scan of the chest, abdomen and pelvis. No scintigraphic evidence of osseous metastasis was reported on bone scan.

In summary, the patient was diagnosed with a triple negative multifocal Adenoid Cystic Carcinoma (ACC) of the left breast, stage I (T1N0M0). The case was discussed in the multidisciplinary breast tumor board (MBTB), and the

recommendations were to go for an upfront surgery, in the form of BCS and SLNB, followed by adjuvant treatment depending on the final pathology.

Treatment

Surgery: The patient underwent ultrasound and wire-guidance left breast conserving surgery with sentinel lymph node biopsy (Figure.4).

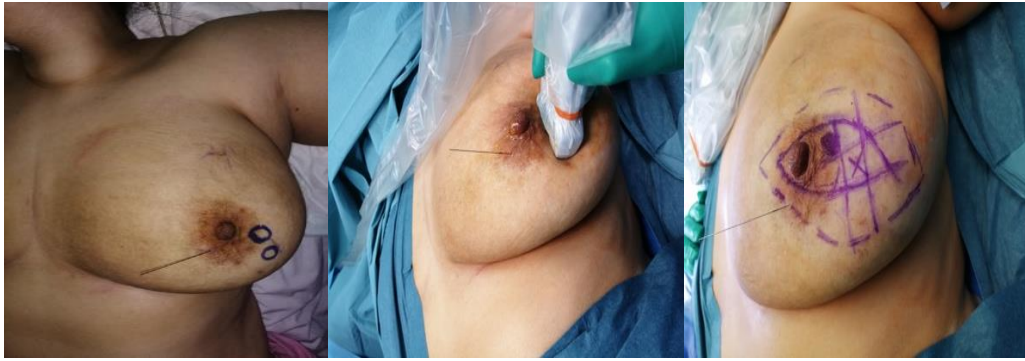

Figure 4a: Preoperative marking and wire localization of the left breast masses, the planned skin incision (Continuous marker line) and intended area of breast resection (dotted marker line) with US-guided localization.

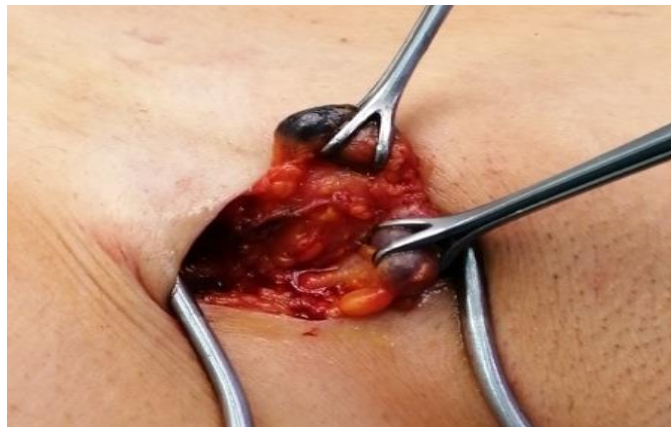

Figure 4b: Sentinel lymph node biopsy using methylene blue dye technique identifying two blue nodes.

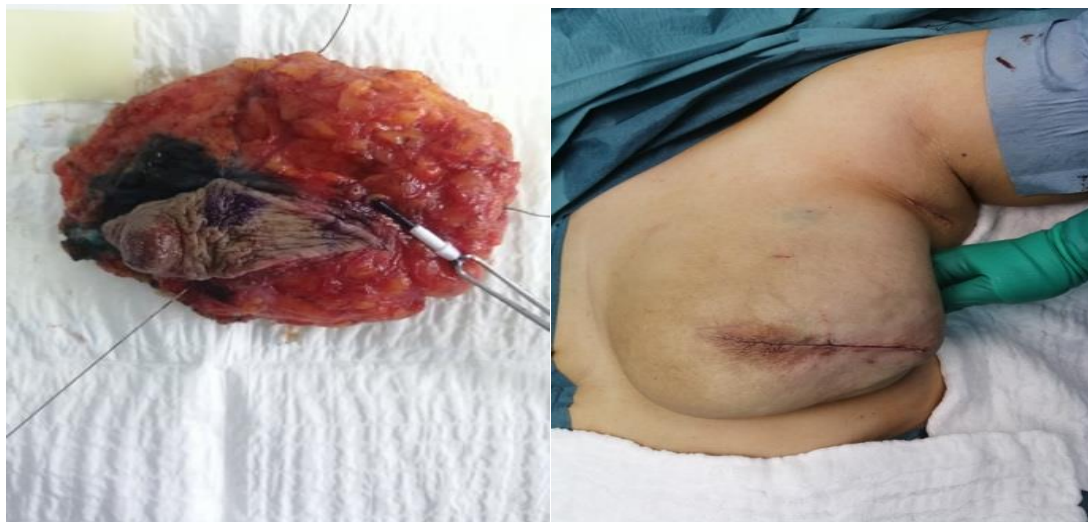


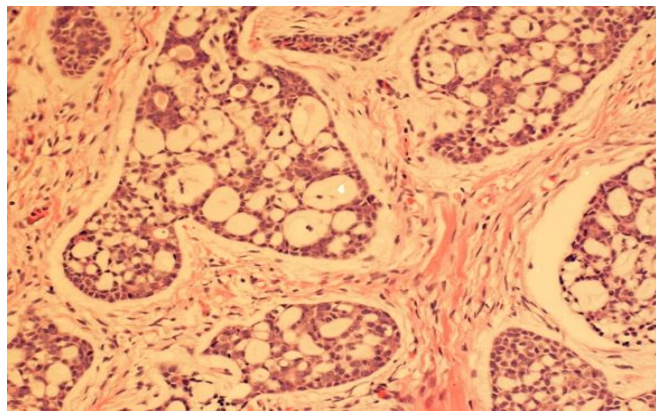
Figure 4c: Postoperative surgical specimen showing the nipple of the left breast with part of the areola and the wire in the center of the deep mass. The marker tip indicates the palpable periareolar mass. The final immediate surgical result is shown.

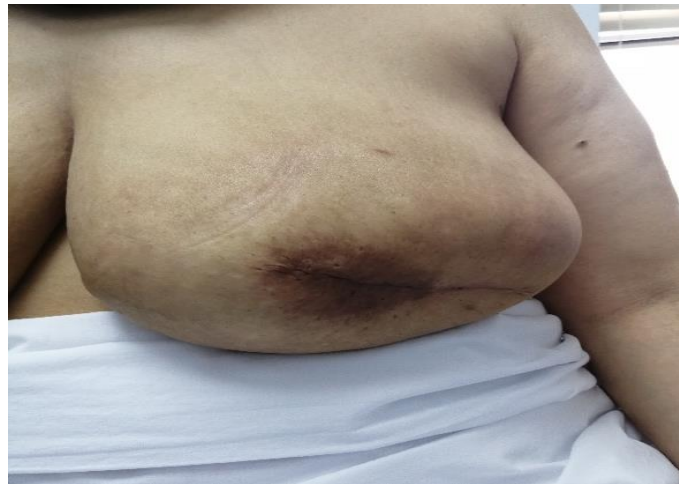

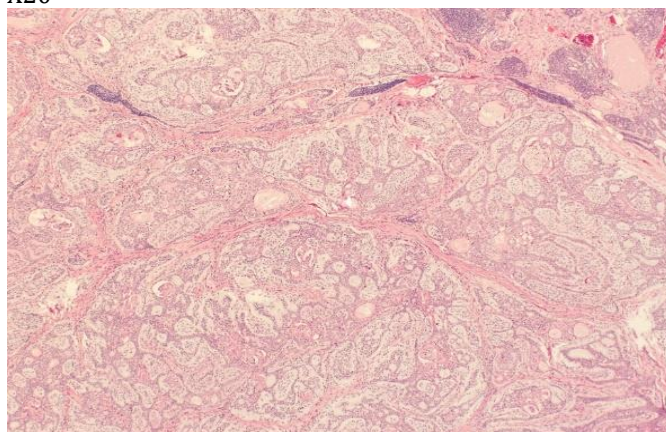
Figure 4D: The 3-month-follow up result of the left breast.

Histopathology

The tumor shows morphologic features most consistent with adenoid cystic carcinoma, particularly in the periphery of the tumor. However, in the central area, the tumor shows more solid growth with focal squamous differentiation and necrosis. This may represent transformation into a higher grade component of the tumor, with all surgical margins being free from malignancy. The immunohistochemistry showed triple negative pattern. The sentinel lymph node biopsy revealed 3 reactive lymph nodes with no evidence of metastasis.



X20



X4

Figure 5: Histopathological pictures for adenoid cystic carcinoma on x20 and x4 magnification.

Adjuvant treatment

Based on the final histopathology report, the MBTB recommended no adjuvant systemic chemotherapy treatment for this patient. The patient received adjuvant radiation therapy for the breast in the form of extended beam radiotherapy (EBRT).

Genetic counseling

Although the disease is triple negative breast cancer, there was no family history suggestive of inheritance. Therefore, no genetic counseling was recommended for this patient.

Follow up

Eleven months after surgery, the clinical and radiological follow up showed no evidence of locoregional recurrence or distant metastasis.

Discussion

Adenoid cystic carcinoma (ACC) is a rare form of well differentiated adenocarcinoma that is most commonly seen in head and neck region, in particular, the salivary glands. Although it can be seen in different sites of the body, ACC comprises less than 0.1% of all breast cancers [3].

In 1856, Bill Roth reported the first case of ACC of the breast with a name of cylindroma. The tumor has been variously called cylindromatous carcinoma, adenocystic basal cell carcinoma and ACC of the breast [4]. In the modern medical era, Geschickter and Copeland in 1945 were the first who described ACC of the breast [5]. While common in salivary gland, ACC can occur at other sites such as in the nasopharynx, trachea, uterine cervix, skin, lungs, esophagus, prostate and kidneys as well as the breast [6].

ACC of the breast occurs between 30 and 90 years of age and more common in women in their fifth and sixth decade of life [7]. Our patient presented at age of 42 and hence, ACC should be considered in the differential diagnosis at a

younger age as well. Typically, it presents as a painful, slow-growing mass, often in the subareolar area, similar to this patient's presentation. Although radiological appearances are often nonspecific both on mammography and breast sonography, the diagnosis can be made by core biopsy. Nevertheless, US and MRI breast may show mixed cystic and solid component, with an irregular shape and irregular margins which raise the bar toward the ACC diagnosis; but yet; not specific [8].

Histologically, it is characterized by the presence of both luminal and myoepithelial components irrespective of site of origin, however, similarities in morphology often do not correspond to the aggressiveness of the tumor, with ACC of the breast often presenting with a more indolent course than its salivary counterpart [9].

ACC of the breast does not usually express ER, PR, and HER2-Neu, and tends to express CK5/6 or EGFR. Although triple-negative breast cancer (TNBC) generally has high proliferative activity, several studies using proliferative markers (e.g., Ki-67) reported a low proliferation rate in ACC of the breast. Immunohistochemically, the luminal cells are positive for CK7, CK8/18, epithelial membrane antigen, and CD117 (c-Kit). The myoepithelial-basal cells are immunoreactive for basal cytokeratins (CK5, CK5/6, CK14, CK17), myoepithelial markers (p63, actin, calponin, S-100 protein), vimentin, and epidermal growth factor receptor (EGFR) [10].

Mastectomy has been known as the standard therapy for patients with ACC for long time, but breast-conserving surgery turns to be a reasonable alternative for patients with ACC of the breast, and adjuvant RT after lumpectomy improved survival rates [11]. With the new techniques of oncoplastic surgery, BCS is becoming more feasible. Our patient had a multifocal disease with two lesions, one of them was superficial and close to the nipple, which precluded sparing the nipple. In the cases where BCS is considered, a multicentric disease has to be excluded. We performed MRI to assess extent of disease and rule out the presence of multicentric disease in view of the multifocality and the density of the breast. The patient underwent an oncoplastic central lumpectomy under the guidance of ultrasound, and wire localization for the nonpalpable deep lesion. By combining different techniques, we were able to completely excise both lesions, obtain a negative surgical margin, and preserve the breast with cosmetically acceptable result.

ACC of the breast is associated with a favorable prognosis when compared to ACC in other locations, with 5 and 10-year overall survival (OS) rates of 94% and 86 % and disease free survival (DFS) rates of 82% and 74%, respectively [12]. Moreover, breast ACC has a more favorable prognosis than breast ductal carcinoma, as lymph node involvement and distant metastasis are uncommon [13]. Preoperative diagnostic images showed no suspicion of lymph node or distal metastasis in our patient. SLNB also revealed no axillary metastasis, supporting the low rate of lymph node involvement in ACC.

In terms of adjuvant treatment, while most clinicians recommend systemic adjuvant chemotherapy for patients with high-grade lesions, aggressive biological subtypes, axillary lymph node or distant metastasis, its role in breast ACC patients remains controversial. The predictive and prognostic factors for breast cancer were found of less clinical significance in patients with breast ACC when determining the adjuvant treatment and the implication of the molecular subtype and the proliferation index of Ki67 was not reproducible as of the classical breast cancer [14]. These tumors usually present in early stage, like this patient, and are amenable to upfront surgery with breast conservation, reducing the advantage of neoadjuvant chemotherapy in down staging the disease that might be required in other tumors [15]. After surgery, these tumors usually remain in early pathological stage due to the low risk of positive sentinel lymph nodes and axillary metastasis as evident in our patient [16]. At this point, the medical oncologist is faced with a great decision to make regarding whether or not to provide adjuvant chemotherapy. This is particularly a hard decision because adjuvant hormonal therapy is not indicated in most of the ACC since it is a hormonal negative cancer, which leaves no systemic alternative to adjuvant chemotherapy. On the other hand, the usually low proliferative ability of this cancer evident in the low Ki67, as seen in our patient (15%), reduces the sensitivity of this tumor to the effect of chemotherapy [14]. Moreover, the major aim of adjuvant systemic chemotherapy is to improve prognosis by reducing the DFS and OS [17,18]. This is particularly crucial for the aggressive types of breast cancer that exhibit high rates of recurrence and carry poor prognosis [19]. However, ACC is a disease of favorable prognosis, with OS reaching 94% and DFS up to 82% [12]. Even when patients with ACC demonstrate local recurrence or distant metastases, a prolonged and indolent clinical course is still likely [20]. This non-aggressive behavior of ACC places adjuvant chemotherapy, along with its significant complications and morbidities, on the weaker side of the scale, encouraging the medical oncologists to vote against the use of adjuvant chemotherapy for ACC.

ACC of the breast has been shown to be driven by MYB proto-oncogene pathway activation, most often reinforced by the MYB-NFIB fusion gene. As treatment of cancer enters a new stage with the development of targeted therapies, the common MYB-NFIB fusion gene may provide new therapeutic avenues for the management of advanced ACC of the breast. Consequently, further functional studies investigating the biological consequences of the MYB gene of function due to the MYB-NFIB fusion are needed. Gene silencing experiments may also be necessary to demonstrate that MYB expression is required for the survival of cancer cells with genetically activated MYB [21].

Conclusion

Adenoid Cystic Carcinoma of the breast is a unique type of breast cancer with good prognosis. Because it is frequently a triple negative disease, oncologists might be tempted to treat it with neoadjuvant chemotherapy as the standard of care for other triple negative breast cancer subtypes. However, surgery is the mainstay of treatment with rising role for adjuvant targeted therapy. The benefit of chemotherapy is questionable, hence, the use of chemotherapy in the neoadjuvant or adjuvant setting is quite controversial, especially in early stage disease. Therefore, early recognition of ACC is important to appropriately tailor the treatment plan with a multidisciplinary team approach, and possibly spare the patient complications and morbidities of chemotherapy.

Conflict of Interest:

I have no disclosure.

Funding Source:

Personal.

Ethics Statement:

The authors are accountable for all aspects of the work in ensuring that questions related to the accuracy or integrity of any part of the work are appropriately investigated and resolved. Written informed consent was obtained from the patient for publication of this study and any accompanying images.

References

1. J.H. McClenathan, G. de la Roza, Adenoid cystic breast cancer, *Am. J. Surg.* 183 (2002) 646–649.
2. Rosai, Ackerman. *Surgically pathology*, vol. 2, 10th edn Elsevier; 2011. p. 1722–23.
3. Millar BA, Kerba M, Youngson B, Lockwood GA, Liu FF. The potential role of breast conservation surgery and adjuvant breast radiation for adenoid cystic carcinoma of the breast. *Breast Cancer Res Treat.* 2004; 87(3): 225–32.
4. Stewart, F.W.: "Tumors of the Breast," in *Atlas of Tumor Pathology*, Washington, DC: Armed Forces Institute of Pathology, sect 9, p 58, 1950.
5. C.F. Geschickter, M.M. Copeland, *Diseases of the Breast: Diagnosis, Pathology, and Treatment*, J.B. Lippincott, Philadelphia, 1945.
6. Peters GN, Wolff M. Adenoid cystic of the breast: report of 11 new cases: Review of the literature and discussion of biological behaviour. *Cancer* 1983; 52:680–686.
7. Suresh Jaywantrao Bhosalea, Ashok Yadavrao Kshirsagara, Rahul Kalyanrao Patila, Jyotsna Vijay Waderb, Nitin Nangarea, Pranita P. Patil Adenoid cystic carcinoma of female breast: A case report, *International Journal of Surgery Case Reports* 4 (2013) 480–482.
8. Wang H, Liu F, Gu R, Li Y, Su F. Rare imaging appearance of adenoid cystic carcinoma of the breast: A case report. *Mol Clin Oncol.* 2017;7(3):473–475.
9. C. Marchiò, B. Weigelt, J.S. Reis-Filho, Adenoid cystic carcinomas of the breast and salivary glands (or 'the strange case of Dr Jekyll and Mr Hyde' of exocrine gland carcinomas), *J. Clin. Pathol.* 63 (2010) 220–228.
10. D. Wetterskog, M.A. Lopez-Garcia, M.B. Lambros, R. A'Hern, F.C. Geyer, F. Milanezi, et al., Adenoid cystic carcinomas constitute a genomically distinct subgroup of triple-negative and basal-like breast cancers, *J. Pathol.* 226 (2012) 84–96.
11. Jia-Yuan Sun et al., Adjuvant radiation therapy and survival for adenoid cystic carcinoma of the breast, *The Breast* 31 (2017) 214–218.
12. Arpino G, Clarck G, Mohsin S, et al. Adenoid cystic of the breast: Molecular markers, treatment, and clinical outcome. *Cancer* 2002; 94:2119–2127.
13. Kleer CG, Oberman HA. Adenoid cystic carcinoma of the breast: Value of histologic grading and proliferative activity. *Am J Surg Pathol* 1998; 22:569–575.
14. Yerushalmi R, Woods R, Ravdin PM, Hayes MM, Gelmon KA: Ki67 in breast cancer: prognostic and predictive potential. *Lancet Oncol* 2010, 11:174–183.
15. Mittendorf EA, Buchholz TA, Tucker SL et al (2013) Impact of chemotherapy sequencing on local-regional failure risk in breast cancer patients undergoing breast-conserving therapy. *Ann Surg* 257(2):173–179.
16. Herzberg AJ, Bossen EH, Walther PJ. Adenoid cystic carcinoma of the breast metastatic to the kidney. A clinically symptomatic lesion requiring surgical management. *Cancer.* 1991;68(5):1015–20.
17. Ito Y, Miyashiro I, Ito H, Hosono S, Chihara D, Nakata-Yamada K, et al. Long-term survival and conditional survival of cancer 620 *Surgery Today* (2019) 49:610–620 1 3 patients in Japan using population-based cancer registry data. *Cancer Sci.* 2014; 105:1480–6.
18. Saadatmand S, Bretveld R, Siesling S, Tilanus-Linthorst MM. Influence of tumour stage at breast cancer detection on survival in modern times: population based study in 173,797 patients. *BMJ.* 2015;351:h4901.
19. Rakha EA, Reis-Filho JS, Baehner F, et al. Breast cancer prognostic classification in the molecular era: the role of histological grade. *Breast Cancer Res* 2010; 12:207.
20. D.L. Page, Adenoid cystic carcinoma of breast, a special histopathologic type with excellent prognosis, *Breast Cancer Res. Treat.* 93 (2005) 189–190.
21. A. Fehr, A. Kovács, T. Löning, H. Frierson, J. van den Oord, G. Stenman, The MYB-NFIB gene fusion-a novel genetic link between adenoid cystic carcinoma and dermal cylindroma, *J. Pathol.* 224 (2011) 322–327.